

Space Reduction After Premature Loss of A Deciduous Second Molar – Retrospective Study.

Hana Pokorná¹, Ivo Marek², Josef Kucera³, Tomáš Hanzelka⁴

¹Department Of Orthodontics, Clinic Of Stomatology, First Medical Faculty Of Charles University And General University Hospital, Prague, Czech Republic

²Department Of Orthodontics, Institute Of Dental Medicine, Medical Faculty Of Palacký University, Olomouc, Czech Republic

³Department Of Orthodontics, Clinic Of Stomatology, First Medical Faculty Of Charles University And General University Hospital, Prague, Czech Republic

⁴Department Of Orthodontics, Clinic Of Stomatology, First Medical Faculty Of Charles University And General University Hospital, Prague, Czech Republic

Abstract:

Aim. The aim of this retrospective study was to determine the amount of space loss after a premature loss of a deciduous second molar in the upper or lower arch and to determine which factors influence this space loss.

Materials and methods. This study contained 44 patients with unilateral premature loss of the deciduous second molar in the upper arch and 55 patients with an unilateral premature loss of the deciduous second molar in the lower arch. Contralateral side with no premature tooth loss served as a control side. Measurements to assess space loss were acquired from plaster models, panoramic and lateral cephalometric X-rays.

Results. Statistically significant space loss ($P < 0.0001$) was observed both in the upper and the lower arches (2.9 ± 1.9 mm and 2.7 ± 1.8 mm, respectively). No significant relationship was observed between the space loss and the height of molar cusps, mandibular line angle or the change of molar relationship.

Conclusion. Although space loss occurred in both arches, twice as much space was lost in the maxilla in comparison to the mean value of leeway space, whereas in the mandible, the space loss is essentially the same as the mean value of leeway space.

Keywords: deciduous molars, premature loss, space loss

I. Introduction

Premature loss of deciduous teeth may be defined as a loss of a deciduous tooth before its natural time of exfoliation and is usually caused by dental caries, trauma or atypical root resorption. The clinical consequences of early deciduous tooth loss have been previously reported in literature. Several studies have been published regarding premature loss of deciduous teeth. However, a report published by Owen [1] highlighted a big diversity of opinions on the clinical consequences of premature loss of deciduous teeth, especially regarding the need of use of space maintainers.

Proponents of space maintainers claim that premature loss of deciduous teeth negatively impacts the developing permanent dentition. According to some authors, an early removal of deciduous teeth may result in an increased amount of crowding [2-7] or an increased space loss during the transition between deciduous and mixed dentition [8-11]. On the contrary, authors opposing the use of space maintainers claim that premature loss of deciduous teeth does not necessarily result in a clinically relevant space loss. They rather attribute the loss of space to the initial tooth size-arch length discrepancy [12-14]. Other authors even claim some reopening of closed space may occur during eruption of permanent teeth, rendering space maintainers unnecessary [2-15].

Therefore, the aim of the present study was to determine whether premature loss of a deciduous second molar results in a clinically relevant loss of space and arch length reduction which would thus require the use of space maintenance devices or active orthodontic space reopening. Another goal of this study was to determine relationship between the space loss and various anatomical variables.

II. Materials and methods

Study participants

Subjects referred for an orthodontic treatment who fulfilled the inclusion criteria were recruited from the Department of Orthodontics, Charles University in Prague, Czech Republic and a private orthodontic practice (Stomma, Breclav, Czech Republic) between January 2011 and March 2012. An informed consent was obtained from all patients and their parents. The following inclusion criteria were used: 1. unilateral premature loss of a deciduous second molar in the upper or lower jaw with no premature loss of other deciduous tooth on

the same side; 2. the second premolar must not be present on the side of deciduous tooth loss; 3. the period from the moment of the loss of deciduous tooth is longer than six months; 4. no premature loss on the contralateral side (control side).

A total of 99 patients who fulfilled the inclusion criteria were divided into two groups based on the localization of the premature tooth loss. Forty-four patients (22 boys, 22 girls; mean age 9.6 ± 1.9) with a unilateral premature loss of the second deciduous molar in the upper dental arch and 55 patients (26 boys, 29 girls; mean age 9.7 ± 2.1) with a unilateral premature loss of the second deciduous molar in the lower arch were included in this study.

Panoramic X-rays (OPG), lateral cephalometric X-rays and plaster models were obtained at the time of the initial orthodontic examination for a comprehensive orthodontic treatment planning. X-rays and plaster models were analyzed. The list of variables measured and description of variables can be derived from Figures 1-4 and Table 1-3. Additional data were also noted from patient files such as patient age at the time of examination and location of the early deciduous second molar loss. Characteristics of the sample file can be derived from Table 1.

Plaster models

From the plaster models, following measurements were recorded: molar relationship on both sides (Angle classification), the height of the highest cusp of the first permanent molar (McH) on the side of the tooth loss measured from the deepest point between the fissures to the highest point of the cusp; the distance between the first permanent molar intercusp fissure and the tip of canine on the side of premature tooth loss and on the control side (M1C) (Fig. 1a; Fig. 2a), the distance between the mesial surface of the permanent first molar and the distal surface of the lateral incisor on the side of the tooth loss and on the control side (M1I2) (Fig. 1b; Fig. 2b) and space analysis (DD; dental discrepancy) of the upper and lower arches was evaluated by the means of Moyers analysis using the prediction table at a level of 75% probability [16]. All measurements on study models were carried out using a digital caliper (Masel Orthodontics, CA, USA) with an accuracy of 0.01 mm. Plaster models of the upper arch were then also scanned with an Epson Perfection 4990 Photo (Meerbusch, Deutschland), and an angle between the line running through mesio-buccal and mesio-palatal cusp of the permanent first molar and the line running through central palatal suture was measured on the side of the premature tooth loss and the control side (MRot) (Fig. 3).

Panoramic X-rays

To avoid bias error due to the method by which the panoramic X-rays are obtained we employed three techniques to measure the inclination of the lower permanent first molar (Fig. 4). An angle between the "mandibular plane" and the long axis of the lower permanent first molar on the side of loss and on the control side (M1ML) was measured. Next, we obtained an angle between the line on the lower border of the mandible between the tooth-bud of the lower permanent second molar and lower second premolar and the long axis of lower permanent first molar on the side of premature tooth loss and on the control side (M1PM). We also measured an angle between the "occlusal plane" and the long axis of lower permanent first molar on the side of premature tooth loss and on the control side (M1OR).

Cephalometric X-rays

From the lateral cephalograms, we measured the angle between the Sella-Nasion line and mandibular line (NSML) and the relation between the posterior and anterior facial height (SGo/NMe). Onyx software (Image Instruments, Germany) was used to evaluate the measurements on panoramic and cephalometric radiographs. All tracings and evaluations were performed by the same operator (HP). A complete list of the variables, detailed description and graphic representation of the parameters can be found in Tables 1 and 2 and Figures 1 - 4.

Error of measurement

Two weeks after measurements were taken, all variables were remeasured from 20 randomly selected patients. Measurement error was calculated using the Dahlberg formula [17] and Pearson correlation coefficient between the first and second measurement. The greatest error of measurement (2.5°) was identified in the inclination of the lower molar to the mandibular plane (M1ML), while the smallest error of measurement (0.2 mm) was found in the molar cusp height and the (McH). The Pearson correlation coefficient showed a good correlation between both measurements. The highest correlation was found in the mandibular plane angle (0.989), on the other hand the molar cusp height measurement shows the smallest correlation (0.746) between both measurements.

Statistical methods

An exploratory test (Shapiro-Wilk normality test) was performed to assess the normality of the distribution for all quantitative variables. Variables with a normal distribution ($P > 0.05$) were analyzed using a paired parametric *t* test. The Pearson correlation coefficient was also used to assess the correlation between chosen variables. In parameters without normal distributions, non-parametric tests were used (Spearman correlation coefficient and a Mann-Whitney U-test). Comparisons of the qualitative variables were performed with the Fisher exact test. A linear multivariate regression analysis was also performed for both jaws with the

loss of space (M1I2) as the dependent variable. Sex, age of the patient, height of the first molar cusp, dental discrepancy and facial divergence were chosen for the independent variables. Statistical analysis was performed using the SPSS statistical software, version 15 (SPSS Inc., Chicago, IL, USA) at $P < 0.05$.

III. Results

The results are presented in Tables 1 through 5 and also in Figures 5 and 6.

Upper jaw

After premature loss of the upper deciduous second molar, the space between the permanent first molar intercuspal fissure and the canine tip (M1C) and distal edge of lateral incisor (M1I2) showed a significant space reduction compared to the control side ($P < 0.0001$ for both the measurements) as the average space loss amounted to 2.9 ± 1.9 mm and 2.9 ± 2.4 mm, respectively (Table 2). The upper first molar on the side of tooth loss also presented with a more pronounced mesiorotation compared to the control side ($P < 0.0001$) by an average of $8.1^\circ \pm 5.8^\circ$ (Table 2). A significant correlation was found between the space loss (M1I2) and the dental discrepancy in the upper jaw ($r = 0.40$; $P = 0.007$) (Table 3). A small but significant negative correlation was also found between the mesial movement of the upper first molar (M1I2) and rotation of the upper first molar (MRot) on the side of premature tooth loss ($r = -0.3$; $P = 0.05$).

On the side of the premature second deciduous molar loss, 9% of patients presented with Class I Angle molar relationship, 32% with half a unit Class II and 59% presented with a full Class II (Fig. 5). On the control side, 46% of the patients presented with Class I Angle relationship, 36% with half a unit Class II and 18% of the cases with full Class II. In 68% of cases, there was a difference in Angle molar relationship between the right and left sides. A total of 14 patients presented with no change in Angle molar relationship between both sides, while in 30 patients some change has occurred. However, no significant difference in space loss (M1C) was found between these groups ($P = 0.971$). Therefore, no relationship between the change in Angle molar relationship and the amount of space loss was identified. A linear multivariate regression model showed no significant predictors for the space loss in the upper jaw.

Lower jaw

The amount of space (M1C and M1I2) on the side of the premature loss of the lower second deciduous molar was significantly reduced when compared to the control side ($P < 0.0001$). The average space loss amounted to 2.7 ± 1.8 mm (M1C) and 2.4 ± 1.6 mm (M1I2) (Table 2 and 3). The space loss in the lower jaw was also due to the increased mesial inclination of the first molars on the side where the premature loss occurred. The inclination of first permanent molars to the mandibular line (M1ML) and second molar-premolar mandibular line (M1PM) was significantly smaller compared to the control side ($P < 0.0001$ for both). The inclination of the first molar to the occlusal plane (M1OR) was significantly bigger in comparison to the control side ($P < 0.0001$). A Pearson correlation analysis revealed significant negative correlation between the loss of space (M1C and M1I2) and dental discrepancy in the lower jaw ($r = -0.38$, $P = 0.005$ and $r = -0.35$, $P = 0.008$). No significant correlation was observed between space loss and other variables.

When molar Angle relationship was examined we found that on the side of premature deciduous molar loss 56% of patients presented with Angle Class I, 16% with half a unit Class II, 4% with Class II and 24% with Class III (Graph 2). On the control side, 34.5% presented with Angle Class I, 40% with half a unit Class II, 22% with Class II and 3.5% presented with Angle Class III (Fig. 6). A total of 20 patients presented with no change in Angle molar relationship between both sides, while in 35 patients the Angle molar relationship was different between both sides. The molar mesial movement (M1C and M1I2) was significantly bigger ($P = 0.01$ and $P = 0.0002$) in patients with the altered Angle molar relationship when compared to the group with the same molar relationship on both sides. While in the first group the space loss amounted to 3.1 ± 1.7 mm (M1C) and 2.9 ± 1.6 mm (M1I2), the latter group presented with only 1.8 ± 1.6 mm and 1.1 ± 1.2 mm, respectively. Thus, significant relationship between space loss and change in molar Angle relationship was found in the lower jaw.

A linear multivariate regression model revealed dental discrepancy in the lower jaw as a statistically significant predictor (beta, -0.320; 95% confidence interval, -0.280-0.016; $P = 0.029$)

IV. Discussion

Despite recent advances in dental care that have increased the number of children appearing with intact dentition [18], premature loss of deciduous teeth still remains a problem. The issues surrounding the early extraction of deciduous teeth and the consequences have been the subjects of a number of studies [7-15, 19-27]. The presented study attempted to describe not only the amount of the space lost after premature loss of second deciduous molar but also the manner by which the space for second premolar is reduced. The purpose of this study was to evaluate especially the clinical impact of such space loss on the developing dentition. We wanted to contribute to the ongoing discussion whether a premature loss of second deciduous molars does or does not require the use of space maintainers. In agreement with previous studies [22, 23] our results also found a

significant loss of space between the permanent first molar intercusp fissure and canine tip after premature loss of second deciduous molar in the upper arch when compared to the control side. However, the clinical significance of such space loss has to be related to the amount of leeway space when indication of space maintainers is concerned. The amount of leeway space in the maxilla is quite variable, ranging from 0.9 mm[28] to 1.5 mm[29]. The average space loss observed in this study was twice as big. A considerable amount of space loss in the upper jaw may also be due to a significant mesial rotation of the first molars around the palatal root. Our results show, that first molars on the control side are significantly less mesiorotated than the first molars on the side where the second deciduous molar was lost. We found that mesiorotation of the first maxillary molar was $8.1^\circ \pm 5.8^\circ$ larger in children with premature deciduous molar loss. The amount of mesiorotation we documented is much higher compared to the results reported by Linder-Aronson¹² who found mesiorotation of $0.67^\circ \pm 3.51^\circ$ in the permanent first maxillary molar after premature loss of deciduous teeth. This result could be affected by the fact, that his study included children with premature loss of the first deciduous molar and deciduous canine.

In this regard, we presume that space loss in the upper arch can be clinically relevant and space maintenance should be considered to prevent complications during following comprehensive orthodontic treatment. Asymmetric distalizing techniques, including extra- or intraoral distalizers, use of temporary anchorage devices, or the need of orthodontics extractions can be avoided by using properly indicated space maintenance techniques. Simple removable appliances or transpalatal arches may be employed for this purpose.

We found an average space loss of 2.7 ± 1.8 mm in the distance between the middle of first permanent molar and middle of deciduous canine (M1C) and 2.4 ± 1.6 mm space loss between the mesial surface of the first molar and distal surface of the lateral permanent incisor (M1I2) on the side with a premature loss when compared to the control side in the lower jaw. The values found in our study are bigger than those found by Liu[23], who reported an average of 1.38 mm space loss in the mandible. Despite the numbers appear to be bigger compared to the results found in the upper jaw, it is important to note, that the leeway space in the mandible is much bigger than in the maxilla as it can oscillate between 2.2 mm[29] and 3.1 mm[16]. The values of space loss found in our study fall within this range. We can thus conclude that the loss of space is not clinically relevant in the lower arch and no space maintenance is needed for most patients.

We have found significant differences in permanent molar inclination after primary second molar loss compared to the control side where no loss occurred. A greater inclination in the first lower molar (a smaller angle) was observed on the side of deciduous molar loss. Our results are in agreement with Pedersen *et al.*[31] who also reported that the permanent first molar may incline after an extraction in the mandible.

However, our results may be influenced by a relatively big variability in age of our patients and also in the variability of time, which elapsed after the deciduous molar extraction. As shown by Northway *et al.*[30] there might be a different dynamics of the space loss when comparing the situation in 6 years and 12 years of age.

The type and quality of intercuspation may also play a role. Lundström[14], Liu[23] and Breakspear[26], have shown that a good intercuspation of the permanent first molars may prevent the mesial shift. Davey[22] focused also on the relationship between cusp height and mesial tooth movement and concluded that cusp height is associated with less mesial movement and space loss. However, according to the multivariate linear regression analysis no significant relationship between cusp height and loss of space in upper or lower jaw could be detected. Dental discrepancy in the lower jaw was identified as the only significant predictor of space loss. Nevertheless, this finding could be expected as these 2 variables are related. We did not observe a relationship between the mandibular plane angle and the degree of space loss, or between the growth rotation type and the degree of space loss after early deciduous tooth loss in either the upper or lower jaw.

The mesial shift and inclination of permanent molars may also present with a change in the Angle classification on the affected side. We found that in the upper arch the mesial tooth movement changed the intermolar relationship towards Angle class II tendency, while in the lower jaw, Class I and Class III were more frequent. There was also a difference in molar articulation between the affected and control sides. In our study, we observed a difference in molar relationship between the left and right sides in 68% of the patients with a premature deciduous loss. Our results support the findings of Pedersen *et al.*[31] who compared the incidence of bilateral distocclusion and documented a significantly lower incidence of distocclusion in the group of children with premature loss of teeth in the lower arch. Northway *et al.*[30] also found that premature loss of the lower deciduous second molar and the subsequent mesial movement of the permanent molars may even lead to mesiocclusion.

Based on our results we may conclude that the consequences of premature primary second molar loss are more clinically relevant in the upper jaw as the space loss exceeds the amount of average leeway space. However, with the big variability of results in mind, the indication of space maintenance should be indicated based on a thorough and comprehensive treatment planning including careful space evaluation and analysis. It is necessary to consider each patient individually to indicate whether the use of a palatal arches, lingual arch or other type of space maintainer will be beneficial for the future orthodontic treatment. The use of lingual arch

space maintainers or other types of space maintainers is also not without a risk. Bond failures and fractures can appear in the lingual arches of fixed space maintainers, hygiene might also be an issue in very young patients. The impact on periodontal health and the risk of enamel decalcification in cases of bad oral hygiene is not negligible. Removable space maintainers are safer in this regard, however their effectivity largely depends on the compliance of the patients.

V. Conclusion

Loss of space both in the upper and lower arches is observed on the side of premature loss of the second deciduous molar when compared to the control side. The amount of space loss in the upper jaw is twice as big when compared to the mean value of leeway space, while in the lower jaw it is essentially the same as the mean value of leeway space. Therefore, space maintenance should be considered after premature loss of second deciduous molars in the upper jaw to prevent space loss and consequent need to employ distalization or extraction techniques.

Conflict of interest

The authors declare no conflict of interest.

References

- [1]. D.G. Owen, The incidence and nature space closure following the premature extraction of deciduous teeth: A literature survey. *American Journal of Orthodontics*, 59(1), 1971,37-49.
- [2]. W.R.Proffit, I.C.Bennett, Space maintenance, serial extraction and the general practitioner. *Journal of American Dental Association*, 74(3),1967, 411-419.
- [3]. D.B.Law, Space maintenance. *Journal of Dentistry for Children*, 25,1958, 130-134.
- [4]. N.H.Olsen, Space maintenance. *Dental Clinics in North America*,7, 1959,339-353.
- [5]. C.F.L.Hinrichsen, Space maintenance in pedodontics. *Australian Dentistry Journal*, 7,1962,451-456.
- [6]. H.M.Kopel, The space maintenance problem in the primary dentition. *Journal of Dentistry for Children*,17(3),1950; 21-30. In: Owen DG. The incidence and nature space closure following the premature extraction of deciduous teeth: A literature survey. *American Journal of Orthodontics*,59(1),1971, 37-49.
- [7]. S.M.Kronfeld. The effects of premature loss of primary teeth and sequence of eruption of permanent teeth on malocclusion. *Journal of Dentistry for Children*, 20,1953,2-13.
- [8]. J.C.Brauer, *Dentistry for children* (McGraw-Hill Book Company, New York, 1964).
- [9]. J.T.Cohen, The selection of cases for space maintainers. *Northwest Dentistry*, 20,1941; 75-84. In: D.G.Owen, The incidence and nature space closure following the premature extraction of deciduous teeth: A literature survey. *American Journal of Orthodontics*, 59(1), 1971, 37-49.
- [10]. K.A.Rosenzweig, H. Klein, Loss of space by extraction of primary molars. *Journal of Dentistry for Children*, 17,1950,275-276.
- [11]. A.L.Ungar, Incidence and effect of premature loss of deciduous teeth. *American Journal of Orthodontics and Oral Surgery*, 24, 1938,613-625.
- [12]. S. Linder-Aronson, The effect of premature loss of deciduous teeth; a biometric study in 14- and 15-year-olds. *Acta Odontologica Scandinavica*, 18,1960,101-122.
- [13]. A.Lundström, Changes in crowding and spacing of teeth with age. *Dental Practice*, 19(6),1969,218-224.
- [14]. A. Lundström, The significance of early loss of deciduous teeth in the etiology of malocclusion. *American Journal of Orthodontics*, 41,1955,819-826.
- [15]. T.E.Magnússon. The effect of premature loss of deciduous teeth on the spacing of the permanent dentition. *European Journal of Orthodontics*, 1(4),1979, 243-249.
- [16]. R.E.Moyers, *Handbook of orthodontics* (4thed., Chicago: YearBook, 1991)198-201.
- [17]. G. Dahlberg, *Statistical methods for medical and biological students* (George Allen Unwin, London, 1940).
- [18]. S.Balkova, *Oral health monitoring in children in Czech Republic* (Public health school, Institute of postgraduate education. Prague, 2010).
- [19]. R.C.Willett. Premature loss of deciduous teeth. *Angle Orthodontist*, 3, 1933,106-111.
- [20]. W.Miyamoto,C.S.Chung,P.K.Yee. Effect of premature loss of deciduous canines and molars on malocclusion of the permanent dentition. *Journal of Dental Research*, 55(4),1976, 584-590.
- [21]. A.Rönnerman, Early loss of primary molars. Relation to space conditions, dental development, facial morphology and the need for orthodontic treatment, Department of Orthodontics, Faculty of Odontology, University of Gothenburg, Gothenburg, 1977. In: J. Pedersen ,K. Stensgaard, B. Melsen, Prevalence of malocclusion in relation to premature loss of primary teeth. *Community Dentistry and Oral Epidemiology*, 6(4), 1978, 204-209.
- [22]. K.W.Davey, Effect of premature loss of primary molars on the anteroposterior position of maxillary first permanent molars and other maxillary teeth. *Journal of Dentistry for Children*, 34(5), 1967,383-394.
- [23]. W.A.Liu. A study of the closure of space following premature loss of deciduous teeth, master's thesis, University of Toronto, Toronto 1949. In: Northway W.M. The not-so-harmless maxillary first molar extraction. *Journal of American Dental Association*, 131(12), 2000,1711-1720.
- [24]. C.M.Seipel, Förtidiga mjölkttandsförluster-effekt och terapi. *Svensk Tandläkare Tidskrift*, 40,1947, 407. In: S.Linder-Aronson, The effect of premature loss of deciduous teeth; a biometric study in 14- and 15-year-olds. *Acta Odontologica Scandinavica*, 18, 1960, 101-122.
- [25]. E.K.Breakspear, Sequelae of early loss of deciduous molars. *Dentistry Records*, 71, 1951,127-134. In: S.Linder-Aronson, The effect of premature loss of deciduous teeth; a biometric study in 14- and 15-year-olds. *Acta Odontologica Scandinavica*, 18, 1960, 101-122.
- [26]. E.K.Breakspear Further observations on early loss of deciduous molars. *Dental Practice*,11, 1961, 233-252.
- [27]. L.M.Clinch, M.J.R Healy. A longitudinal study of the results of premature extraction of deciduous teeth between 3-4 and 13-14 years of age. *Dental Practice*, 9,1959,109-127.

- [28]. H.N.Nance. The limitations of orthodontic treatment. Part I. American Journal of Orthodontics and Oral Surgery, 33,1947,177-223.
- [29]. C.F.A.Moorrees,J.M.Chadha, Crown diameters of corresponding tooth groups in the deciduous and permanent dentition. Journal ofDentistry Research, 41, 1962,466-470.
- [30]. W.M.Northway, R.L. Wainright, A. Demirjian, Effect of premature loss of deciduous molars. Angle Orthodontist, 54(4),1984, 295-329.
- [31]. J. Pedersen,K. Stensgaard andB.Melsen. Prevalence of malocclusion in relation to premature loss of primary teeth. Community Dentistry and Oral Epidemiology, 6(4), 1978,204-209.

Figure legends:

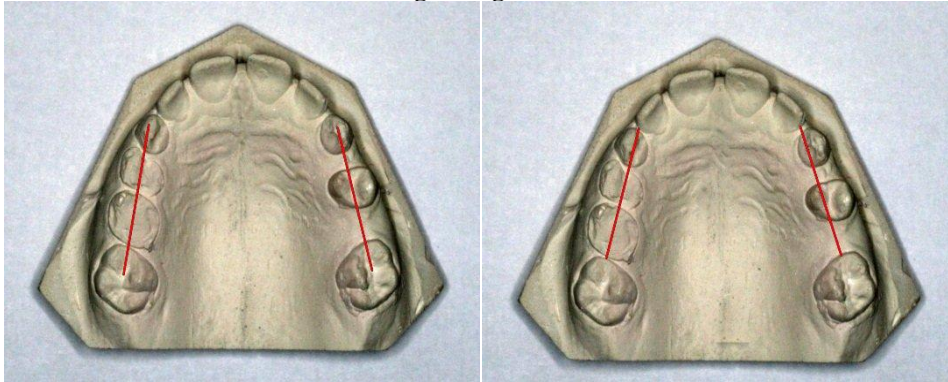


Fig. 1. Space evaluation after premature tooth loss in the upper jaw: a. The distance between the first permanent molar intercusp fissure and the tip of canine (M1C); b. the distance between the mesial surface of the permanent first molar and the distal surface of the lateral incisor (M1I2).

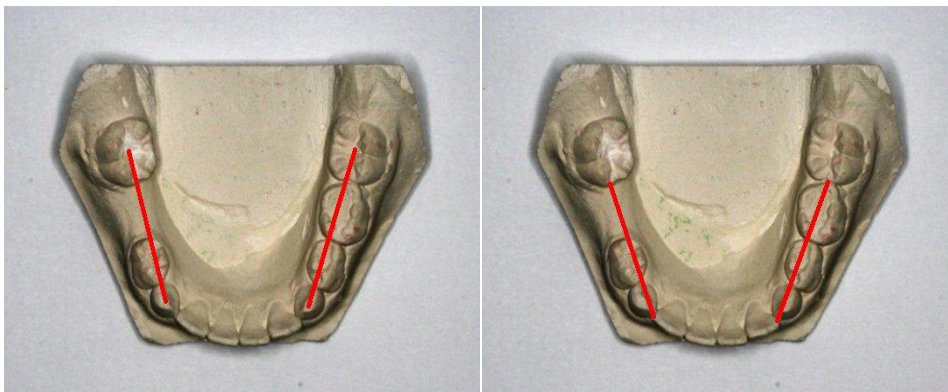


Fig. 2. Space evaluation after premature tooth loss in the lower jaw: a. The distance between the first permanent molar intercusp fissure and the tip of canine (M1C); b. the distance between the mesial surface of the permanent first molar and the distal surface of the lateral incisor (M1I2)."

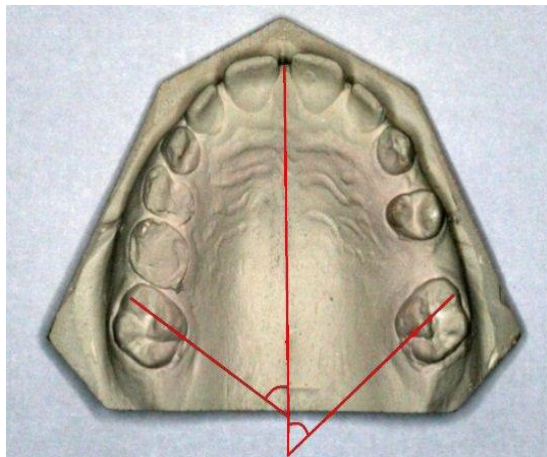


Fig. 3.Amount of mesial molar rotation after premature tooth loss in the upper jaw (MRot).

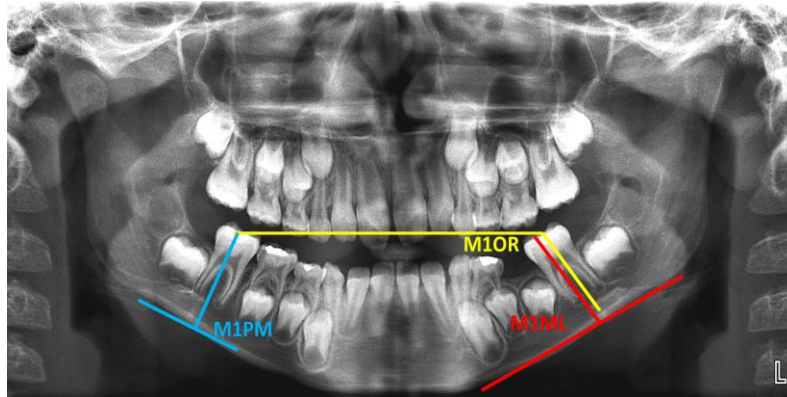


Fig. 4. Panoramic X-ray measurements evaluating mesial first permanent molar inclination.

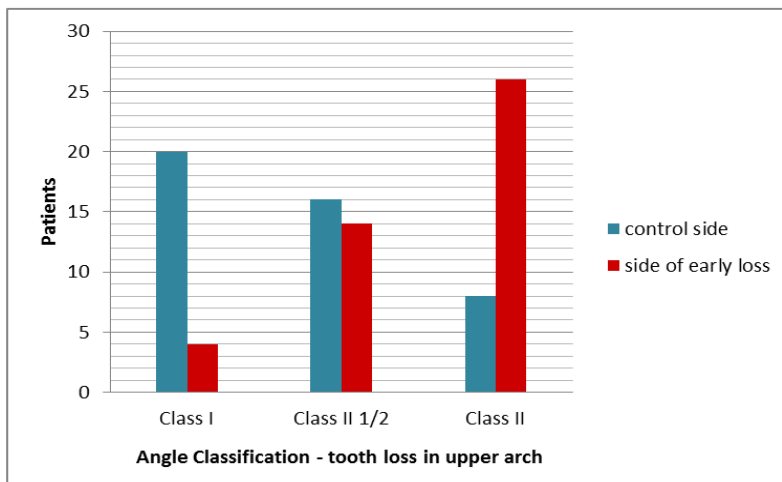


Fig. 5. Comparison of Angle molar classification between both sides in the upper jaw.

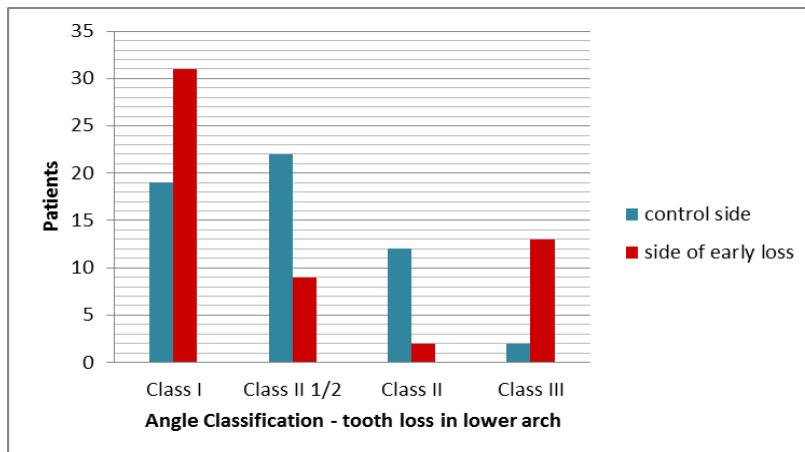


Fig. 6. Comparison of Angle molar classification between both sides in the lower jaw.

Table 1. Characteristics of patients with a second deciduous molar loss in upper and lower jaw.

	Upper jaw (n = 44)	Lower jaw (n = 55)
Sex (M/F)	22 M/22 F	26 M/29 F
Age	9.6 ± 1.9	9.7 ± 2.1
Location of premature loss		
	22	22
		28
		27
McH	2.1 ± 0.4	1.9 ± 0.4
DD	-3.2 ± 3.2	-0.7 ± 3.5
NSML	32.9 ± 5.6	34.2 ± 5.8
SGo/NMe	65.7 ± 6.3	64.5 ± 5.2

Table 2. Study model and panoramic X-ray measurements in both jaws.

Upper jaw (n = 44)	Side of premature loss	Control side	Difference	Sig
MIC	21.4 ± 2.2	24.3 ± 1.3	2.9 ± 1.9	<0.0001
M1I2	19.5 ± 2.2	22.4 ± 1.3	2.9 ± 2.4	<0.0001
MROt	47.9 ± 7.2	55.9 ± 5.9	8.1 ± 5.8	<0.0001
MIC	22.6 ± 2.1	25.2 ± 1.6	2.7 ± 1.8	<0.0001
M1I2	20.3 ± 1.9	22.7 ± 1.4	2.4 ± 1.6	<0.0001
M1ML	86.0 ± 5.6	92.6 ± 4.7	6.7 ± 6.9	<0.0001
M1PM	90.7 ± 5.4	97.0 ± 5.5	6.3 ± 7.9	<0.0001
M1OR	115.0 ± 7.2	107.9 ± 6.9	-7.1 ± 6.8	<0.0001

Table 3. Correlation coefficients between space loss and other variables in upper jaw

Upper jaw	MIC		M1I2	
	corr	p	corr	p
McH	0.17	0.27	0.04	0.79
DD	0.28	0.07	0.40	0.007
NSML	0.11	0.49	0.03	0.86
SGo/NMe	-0.07	0.67	0.05	0.77
MROt	-0.06	0.68	-0.30	0.05

Table 4. Correlation coefficients between space loss and other variables in lower jaw

Lower jaw	MIC		M1I2	
	corr	p	corr	p
McH	0.04	0.76	-0.10	0.47
DD	-0.38	0.005	-0.35	0.008
NSML	0.10	0.47	0.17	0.21
SGo/NMe	-0.14	0.32	-0.20	0.14
M1ML	0.16	0.24	0.18	0.20
M1PM	0.25	0.07	0.23	0.10
M1OR	-0.23	0.09	-0.22	0.14

Tab. 5. Multivariate linear regression model for M1I2 as a dependent variable in upper and lower jaw.

M1I2	UPPER JAW				LOWER JAW			
	Beta	Sig	Lower bound	Upper bound	Beta	Sig	Lower bound	Upper bound
Sex (male/female)	0,015	0,928	-1,524	1,667	0,185	0,171	-0,267	1,461
Age	0,165	0,312	-0,209	0,635	0,042	0,777	-0,198	0,263
McH	-0,033	0,845	-2,498	2,054	-0,104	0,429	-1,433	0,619
DD	-0,249	0,146	-0,434	0,067	-0,320	0,029	-0,280	-0,016
NSML	0,053	0,844	-0,208	0,253	-0,147	0,518	-0,166	0,085